

Clozapine-induced hypersensitivity myocarditis presenting as sudden cardiac death

Natraj Katta^a, Sudarshan Balla^a, Kul Aggarwal^a

Katta N, Balla S, Aggarwal K. Clozapine-induced hypersensitivity myocarditis presenting as sudden cardiac death. *Autopsy Case Rep* [Internet]. 2016;6(4):9-13. <http://dx.doi.org/10.4322/acr.2016.054>

ABSTRACT

Hypersensitivity myocarditis is a rare but serious adverse effect of clozapine, a commonly used psychiatric drug. We report the case of sudden cardiac death from clozapine-induced hypersensitivity myocarditis diagnosed at autopsy. A 54-year-old Caucasian male on clozapine therapy for bipolar disorder presented with a sudden onset of shortness of breath. Laboratory studies were significant for elevated N-terminal prohormone of brain natriuretic peptide. During his hospital stay, the patient died of sudden cardiac arrest from ventricular tachycardia. The autopsy revealed hypersensitivity myocarditis, which usually occurs in the first 4 weeks after the initiation of clozapine. A 4-week monitoring protocol, including laboratory assessment of troponin and C-reactive protein, may assist in the early diagnosis of this potentially fatal condition.

Keywords

Clozapine; Hypersensitivity; Myocarditis; Death, Sudden, Cardiac

INTRODUCTION

Clozapine, a newer atypical antipsychotic, is often considered as the gold standard therapy in the management of treatment-resistant schizophrenia,¹ and has often been used off-label for the treatment of bipolar disorder.² It is associated with minor adverse effects, such as sedation, weight gain, constipation, urinary incontinence, and severe adverse effects, such as agranulocytosis and seizures.³ Also, clozapine has been associated with an underreported but serious condition known as clozapine-induced hypersensitivity myocarditis (CIHSM).⁴⁻⁷ Although there are few reported cases of in vivo diagnosis and successful treatment,⁸⁻¹⁰ unfortunately CIHSM is often diagnosed only by histological examination of an autopsied heart specimen as it can potentially cause sudden cardiac death (SCD). Awareness of this condition,

and understanding the clinical clues and diagnostic methods, may help in the early diagnosis of CIHSM and enable appropriate intervention to prevent SCD.

CASE REPORT

The patient was a 54-year-old Caucasian male with a history of anxiety, bipolar disorder, and chronic kidney disease (CKD) stage III secondary to hypertensive nephrosclerosis. He was referred to our facility for the evaluation of shortness of breath and tachycardia. The patient attributed his shortness of breath to anxiety. He denied any chest pain or palpitations. There was no history of orthopnea, paroxysmal nocturnal dyspnea, or lower limb swelling. His vital signs showed

^a Division of Cardiovascular Medicine - Department of Medicine - University of Missouri School of Medicine, Columbia/MO, USA.



a regular heart rate of 110 bpm, a respiratory rate of 20/min, and blood pressure of 118/78 mmHg. He was afebrile and had peripheral capillary oxygen saturation of 96% on room air. Jugular venous pressure was normal. For the past 6 weeks he had been treated with clozapine for his psychiatric illness.

An electrocardiogram showed sinus tachycardia with nonspecific ST-T wave changes. The chest radiograph was unremarkable. Troponin T (Tn-T) was normal at < 0.01 ng/mL (normal range [NR]: < 0.01 ng/mL), but N-terminal prohormone of brain natriuretic peptide (NT-proBNP) was elevated at 750 pg/mL (NR: 0.0-125.0 pg/mL) and D-Dimer was elevated at 3.1 mcg/mL (NR: 0.00-0.50 mcg/mL). A complete blood count with differential was normal with a normal eosinophil count. The serum chemistry was significant for creatinine of 1.6 mg/dL (NR: 0.67-1.17 mg/dL), which was unchanged from the baseline. A chest radiograph showed minimal lineal bibasilar atelectasis. A ventilation perfusion scan was performed, which suggested low probability for pulmonary embolism. There was no evidence of deep venous thrombosis on venous ultrasound of the lower limbs. Transthoracic echocardiogram revealed normal left ventricular systolic function (the ejection fraction was calculated at 57.7% using the Teicholz formula) with mild diastolic dysfunction.

On the third day of admission, the patient sustained sudden cardiac arrest due to pulseless ventricular tachycardia. An autopsy of the heart was performed for transplant purposes, excluding other

body parts, as per the family request. The pre-dissection weight of the heart was 319 g (NR: 338–589 g). All four chambers were normal in size. All four valves leaflets were thin, delicate, and freely movable without vegetation. Sections of the coronary arteries were free of significant atherosclerotic disease. No acute intraluminal coronary thrombus was seen. The sections of the right atrial wall revealed normal sinoatrial node. Histological examination of myocardial sections showed patchy perivascular mixed inflammation with some associated fibrosis (Figure 1A). There were histiocytes, lymphocytes, and neutrophils, as well as eosinophils with interstitial inflammation (Figure 1B). There was no significant myocyte damage. The diagnosis of CIHSM was made and was attributed as the cause of SCD.

DISCUSSION

Clozapine, although commonly used for treatment-resistant schizophrenia, is occasionally used as an off-label indication for bipolar disorder.^{1,2} Neutropenia and seizures are well-reported serious adverse effects of clozapine.³ CIHSM, a drug-related myocarditis, is an under-reported severe condition.⁴⁻⁷

Hypersensitivity myocarditis is the most common form of drug-induced myocardial disease, among others, such as toxic myocarditis, endocardial fibrosis (caused by medications such as fenfluramine, ergotamine tartrate, phentermine, methysergide), drug-induced cardiomyopathy (caused by medications such as

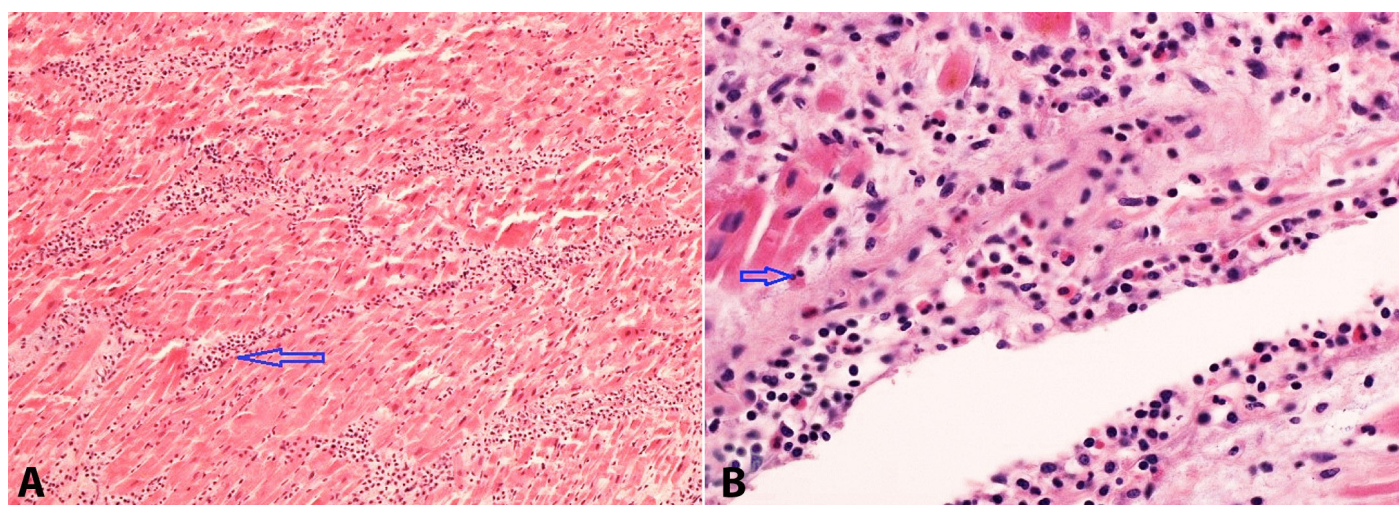


Figure 1. Photomicrography of the myocardium. **A** - A “roadmap” pattern of perivascular mixed inflammation with eosinophils (arrow) (H&E, 100X); **B** - Higher power view of the perivascular inflammation showing small round lymphocytes, histiocytes, and eosinophils with bilobed nuclei (arrow) (H&E, 400X).

anthracycline, chloroquine), and giant cell myocarditis.¹¹ Several medications, including clozapine, sulfonamides, penicillin, methyldopa, furosemide, tetracycline, azithromycin, aminophylline, and phenytoin are associated with hypersensitivity myocarditis.¹²⁻¹⁴ The pathological process of hypersensitivity myocarditis comprises an eosinophilic infiltration of the myocardium; therefore, it is considered as a sub-type of eosinophilic myocarditis.^{11,15} Eosinophilic myocarditis is frequently associated with systemic hypereosinophilic conditions, such as hypereosinophilic syndrome, Churg-Strauss syndrome, and parasitic infections that have a high peripheral eosinophil count, as well as patients awaiting cardiac transplant who are on intravenous inotropic agents.^{11,15,16} In contrast, the peripheral eosinophil count is often normal in hypersensitivity myocarditis; therefore, it is not useful for a diagnosis. In our patient, parasitic infections and hypereosinophilic systemic diseases were considered less likely as he had a normal peripheral eosinophil count.

Kilian et al.⁵ first described the association between clozapine and myocarditis in 1999. The reported incidence of CIHSM is widely variable. A 2007 retrospective analysis study of 116 cases in Australia reported an incidence between 0.7% and 1.2% of all clozapine treated cases.⁴ The incidence of myocarditis in some studies was noted to be as high as 8.5%.⁶ Since many patients are either undiagnosed or unreported, it is challenging to assess the accurate incidence of CIHSM.

Several studies have suggested a wide range of onset times of CIHSM symptoms after the initiation of clozapine. While cases have been reported as early as 16 days after the initiation of the drug,⁴ up to 75% of the patients develop symptoms within the first month,¹⁷ 85% cases within the first two months,¹⁷ and a few cases may develop symptoms up to 2 years later.⁴

Initial presenting symptoms of CIHSM can be nonspecific flu-like symptoms, such as malaise, fatigue, pleuritic chest pain, cough, and rash, and may be evident as a clinical sign of hypersensitivity.¹¹ Sinus tachycardia is one of the early clinical signs detected in 90% of the CIHSM cases.¹⁸ Clozapine may induce autonomic imbalance, decreased parasympathetic tone, and increased sympathetic drive; in so doing, it can cause resting tachycardia.¹⁹ Although the exact mechanism of CIHSM is unclear, increased circulating plasma catecholamine from a high sympathetic drive could be

responsible for triggering an inflammatory response resulting in myocarditis; therefore, beta-adrenergic blockade may reduce the incidence and the severity.²⁰ Wang²⁰ illustrated that clozapine-treated mice had a substantial increase in myocardial inflammation that correlated with higher plasma catecholamine levels, and that subsequent blockade of beta-adrenergic receptors with propranolol significantly attenuated these effects.²⁰ During hospitalization, our patient had persistent sinus tachycardia with a heart rate ranging from 110 bpm to 140 bpm, which reduced to 101 bpm with the use of metoprolol.

Further diagnostic clues may emanate from measuring cardiac troponin, NT-proBNP, and C-reactive protein (CRP) as they are often elevated in CIHSM. In a case control study conducted in Australia, Ronaldson et al.⁷ showed that 90% of the diagnosed CIHSM cases had elevated troponins within 4 weeks of starting clozapine; whereas CRP was elevated in 70% of these cases. However, in five cases where Tn-T was normal, CRP was elevated. The study also suggested that a combination of CRP (> 100 mg/L) and cardiac troponin (> 2 upper limit normal) had 100% sensitivity in identifying CIHSM.¹⁸ Based on these results, Ronaldson et al.¹⁸ proposed a monitoring protocol, including periodical assessment of cardiac troponin and CRP, during the first 4 weeks of initiation of the drug regardless of symptoms. Our patient had normal Tn-T, and CRP was not measured. Another cardiac biomarker NT-proBNP has been widely used in diagnosing and estimating the prognosis of heart failure; however, its role in myocarditis has not been well studied. Since our patient had elevated NT-proBNP, we believe further studies are warranted to better define its role in myocarditis in general, and CIHSM in particular.

An echocardiogram may provide diagnostic information with wall motion abnormalities in severe CIHSM cases, but in cases of less severe focal disease its utility is questionable as the findings may be nonspecific. Ronaldson et al.¹⁸ reported impaired left ventricular function in 66% of their patients diagnosed with CHISM; however, they did not specify if it was a systolic or a diastolic dysfunction. Our patient had normal systolic function with mild diastolic dysfunction, which is a common finding in his age group.

Similar to other types of myocarditis, the diagnostic modality of choice for CIHSM is cardiac magnetic resonance imaging (CMR). The use of T2 weighted

images increased the sensitivity to 84% and the specificity to 74% in diagnosing myocarditis.²¹ Contrast enhancement with gadolinium has been shown to further increase diagnostic accuracy.^{21,22}

Endomyocardial biopsy (EMB) is often considered the gold standard test in detecting myocarditis.²³ The 2007 ACC/AHA/ESC/HFSA guidelines recommend EMB in cases of suspected hypersensitivity myocarditis.²⁴ EMB also yields low sensitivity in focal myocarditis. CMR has been shown to improve the diagnostic yield of EMB by aiding targeted area biopsy.²²

Similar to other drug-induced hypersensitivity myocarditis, the treatment of CIHSM includes supportive management and discontinuation of the drug. Significant clinical improvement can be expected in patients with myocarditis with intensive hemodynamic monitoring and supportive management.²⁵ Although the role of corticosteroids is questionable, we did find a few published case reports on the beneficial effect of steroids in severe cases of myocarditis complicated by cardiogenic shock.^{14,26-28} Also, azathioprine has been used as an adjunct in the treatment of patients with steroid-resistant hypersensitivity myocarditis and cardiogenic shock.²⁹

CONCLUSION

We report the case of CIHSM presenting as SCD where the diagnosis was made at autopsy. Clozapine-induced hypersensitivity myocarditis is a rare and serious condition. A high index of clinical suspicion is needed for a timely diagnosis. The vast majority of these patients may present with vague symptoms or are unable to relay their symptoms. Serum cardiac biomarkers and imaging modalities, including CMR, can help in the diagnosis of CIHSM. Implementing a 4-week monitoring protocol with periodical assessment of troponins, after the initiation of clozapine, CRP may be a sensitive tool in the early diagnosis of this serious adverse reaction.

REFERENCES

1. Asenjo Lobos C, Komossa K, Rummel-Kluge C, et al. Clozapine versus other atypical antipsychotics for schizophrenia. *Cochrane Database Syst Rev*. 2010;(11):Cd006633. PMID:21069690.

2. Kant R, Chalansani R, Chengappa KN, Dieringer MF. The off-label use of clozapine in adolescents with bipolar disorder, intermittent explosive disorder, or posttraumatic stress disorder. *J Child Adolesc Psychopharmacol*. 2004;14(1):57-63. PMID:15142392. <http://dx.doi.org/10.1089/104454604773840490>.
3. Miller DD. Review and management of clozapine side effects. *J Clin Psychiatry*. 2000;61(Suppl 8):14-7. PMID:10811238.
4. Haas SJ, Hill R, Krum H, et al. Clozapine-associated myocarditis: a review of 116 cases of suspected myocarditis associated with the use of clozapine in Australia during 1993-2003. *Drug Saf*. 2007;30(1):47-57. PMID:17194170. <http://dx.doi.org/10.2165/00002018-200730010-00005>.
5. Kilian JG, Kerr K, Lawrence C, Celermajer DS. Myocarditis and cardiomyopathy associated with clozapine. *Lancet*. 1999;354(9193):1841-5. PMID:10584719. [http://dx.doi.org/10.1016/S0140-6736\(99\)10385-4](http://dx.doi.org/10.1016/S0140-6736(99)10385-4).
6. Reinders J, Parsonage W, Lange D, Potter JM, Plevier S. Clozapine-related myocarditis and cardiomyopathy in an Australian metropolitan psychiatric service. *Aust N Z J Psychiatry*. 2004;38(11-12):915-22. PMID:15555025. <http://dx.doi.org/10.1080/j.1440-1614.2004.01481.x>.
7. Ronaldson KJ, Fitzgerald PB, McNeil JJ. Clozapine-induced myocarditis, a widely overlooked adverse reaction. *Acta Psychiatr Scand*. 2015;132(4):231-40. PMID:25865238. <http://dx.doi.org/10.1111/acps.12416>.
8. Hatton JL, Bhat PK, Gandhi S. Clozapine-induced myocarditis: recognizing a potentially fatal adverse reaction. *Tex Heart Inst J*. 2015;42(2):155-7. PMID:25873829. <http://dx.doi.org/10.14503/THIJ-13-3633>.
9. Park Y, Ahn SG, Ko A, et al. Hypersensitivity myocarditis confirmed by cardiac magnetic resonance imaging and endomyocardial biopsy. *Korean J Intern Med*. 2014;29(2):236-40. PMID:24648808. <http://dx.doi.org/10.3904/kjim.2014.29.2.236>.
10. Pieroni M, Cavallaro R, Chimenti C, Smeraldi E, Frustaci A. Clozapine-induced hypersensitivity myocarditis*. *Chest*. 2004;126(5):1703-5. PMID:15539749. <http://dx.doi.org/10.1378/chest.126.5.1703>.
11. Gerald J, Berry KAA. In *Myocarditis: from Bench to Bedside*. 2nd ed. Totowa: Humana Press; 2003. p. 325-70.
12. Ben m'rad M, Leclerc-Mercier S, Blanche P, et al. Drug-induced hypersensitivity syndrome: clinical and biologic disease patterns in 24 patients. *Medicine*. 2009;88(3):131-40. PMID:19440116. <http://dx.doi.org/10.1097/MD.0b013e3181a4d1a1>.
13. Pursnani A, Yee H, Slater W, Sarswat N. Hypersensitivity myocarditis associated with azithromycin exposure. *Ann Intern Med*. 2009;150(3):225-6. PMID:19189924. <http://dx.doi.org/10.1213/00006123-200903000-00005>.

- dx.doi.org/10.7326/0003-4819-150-3-200902030-00027.
14. Taliercio CP, Olney BA, Lie JT. Myocarditis related to drug hypersensitivity. *Mayo Clin Proc.* 1985;60(7):463-8. PMID:4010343. [http://dx.doi.org/10.1016/S0025-6196\(12\)60870-2](http://dx.doi.org/10.1016/S0025-6196(12)60870-2).
 15. Magnani JW, Dec GW. Myocarditis: current trends in diagnosis and treatment. *Circulation.* 2006;113(6):876-90. PMID:16476862. <http://dx.doi.org/10.1161/CIRCULATIONAHA.105.584532>.
 16. Takkenberg JJ, Czer LS, Fishbein MC, et al. Eosinophilic myocarditis in patients awaiting heart transplantation. *Crit Care Med.* 2004;32(3):714-21. PMID:15090952. <http://dx.doi.org/10.1097/01.CCM.0000114818.58877.06>.
 17. Hägg S, Spigset O, BAHons AB, Söderström TG. Myocarditis related to clozapine treatment. *J Clin Psychopharmacol.* 2001;21(4):382-8. PMID:11476122. <http://dx.doi.org/10.1097/00004714-200108000-00005>.
 18. Ronaldson KJ, Fitzgerald PB, Taylor AJ, Topliss DJ, McNeil JJ. A new monitoring protocol for clozapine-induced myocarditis based on an analysis of 75 cases and 94 controls. *Aust N Z J Psychiatry.* 2011;45(6):458-65. PMID:21524186. <http://dx.doi.org/10.3109/00048674.2011.572852>.
 19. Cohen H, Loewenthal U, Matar M, Kotler M. Association of autonomic dysfunction and clozapine. Heart rate variability and risk for sudden death in patients with schizophrenia on long-term psychotropic medication. *Br J Psychiatry.* 2001;179(2):167-71. PMID:11483480. <http://dx.doi.org/10.1192/bjpp.179.2.167>.
 20. Wang JF, Min JY, Hampton TG, et al. Clozapine-induced myocarditis: role of catecholamines in a murine model. *Eur J Pharmacol.* 2008;592(1-3):123-7. PMID:18627770. <http://dx.doi.org/10.1016/j.ejphar.2008.06.088>.
 21. Abdel-Aty H, Boye P, Zagrosek A, et al. Diagnostic performance of cardiovascular magnetic resonance in patients with suspected acute myocarditis: comparison of different approaches. *J Am Coll Cardiol.* 2005;45(11):1815-22. PMID:15936612. <http://dx.doi.org/10.1016/j.jacc.2004.11.069>.
 22. Mahrholdt H, Goedecke C, Wagner A, et al. Cardiovascular magnetic resonance assessment of human myocarditis: a comparison to histology and molecular pathology. *Circulation.* 2004;109(10):1250-8. PMID:14993139. <http://dx.doi.org/10.1161/01.CIR.0000118493.13323.81>.
 23. Laser JA, Fowles RE, Mason JW. Endomyocardial biopsy. *Cardiovasc Clin.* 1985;15(1):141-63. PMID:3916087.
 24. Cooper LT, Baughman KL, Feldman AM, et al. The Role of Endomyocardial Biopsy in the Management of Cardiovascular Disease: A Scientific Statement From the American Heart Association, the American College of Cardiology, and the European Society of Cardiology Endorsed by the Heart Failure Society of America and the Heart Failure Association of the European Society of Cardiology. *J Am Coll Cardiol.* 2007;50(19):1914-31. PMID:17980265. <http://dx.doi.org/10.1016/j.jacc.2007.09.008>.
 25. Yanagisawa T, Inomata T, Watanabe I, et al. Clinical significance of corticosteroid therapy for eosinophilic myocarditis. *Int Heart J.* 2011;52(2):110-3. PMID:21483171. <http://dx.doi.org/10.1536/ihj.52.110>.
 26. Kim CH, Vlietstra RE, Edwards WD, Reeder GS, Gleich GJ. Steroid-responsive eosinophilic myocarditis: diagnosis by endomyocardial biopsy. *Am J Cardiol.* 1984;53(10):1472-3. PMID:6720598. [http://dx.doi.org/10.1016/S0002-9149\(84\)91473-5](http://dx.doi.org/10.1016/S0002-9149(84)91473-5).
 27. Watanabe N, Nakagawa S, Fukunaga T, Fukuoka S, Hatakeyama K, Hayashi T. Acute necrotizing eosinophilic myocarditis successfully treated by high dose methylprednisolone. *Jpn Circ J.* 2001;65(10):923-6. PMID:11665801. <http://dx.doi.org/10.1253/jcj.65.923>.
 28. Zaacks SM, Klein L, Tan CD, Rodriguez ER, Leikin JB, Leikin J. Hypersensitivity myocarditis associated with ephedra use. *J Toxicol Clin Toxicol.* 1999;37(4):485-9. PMID:10465246. <http://dx.doi.org/10.1081/CLT-100102440>.
 29. Aggarwal A, Bergin P, Jessup P, Kaye D. Hypersensitivity myocarditis presenting as cardiogenic shock. *J Heart Lung Transplant.* 2001;20(11):1241-4. PMID:11704488. [http://dx.doi.org/10.1016/S1053-2498\(01\)00313-8](http://dx.doi.org/10.1016/S1053-2498(01)00313-8).

Conflict of interest: None

Submitted on: September 13th, 2016

Accepted on: November 22nd, 2016

Correspondence

Natraj Katta

Division of Cardiovascular Medicine - Department of Medicine

One Hospital Drive, CE306, Columbia, MO 65212 - USA

Phone: +1 (573) 882-7272/Fax: +1 (573) 884-7743

kattan@health.missouri.edu